



## A Field Guide to the Excavation of Inhumated Human Remains

January 2005



©OSSAFreelance 2005

## **Field Guide to the Excavation of Inhumated Human Remains**

### **Introduction**

The purpose of this guide is to act as a brief overview of issues relating to the recovery and recording of inhumated human remains for field archaeologists. Hopefully, it will provide an insight for those who may be less experienced in handling human remains into why we excavate them, what information an osteoarchaeologist hopes to gain from them, how to go about excavating human skeletal remains and what to look out for during the process of their recovery. This guide also aims to provide a few pointers to maximise the potential information retrieved.

### **Aims of Excavating Inhumated Remains: the Osteoarchaeological Perspective**

Before tackling the issues of how to excavate and recover human remains, we need to cover the main reasons for digging up human bones and what an osteoarchaeologist aims to get from analysing the remains. An osteoarchaeologist studies the remains of past populations for several reasons; to study the diseases of past populations and to understand how well they have adapted to their environment in terms of morbidity, to analyse age and sex profiles of populations to see how demographic profiles have changed over the centuries to try and understand patterns of mortality or to assess how funerary customs and social attitudes to death have changed through time. There may also be studies regarding more specific areas such as dietary practices from chemical analyses of teeth, the recording of estimated stature and bone development to understand if people grew and matured differently in the past or the recording of a particular disease to see how its prevalence rates differ between male and females or over time.

In order to carry out this level of analysis, the basic information about each individual skeleton recovered needs to be recorded. The more bones that are recovered intact, the more information can be recorded and, therefore, the more detailed and complete later analytical studies can be. The basic information that is recorded by the osteoarchaeologist at the first stage of post-excavation analysis is an inventory of all the bones and teeth that are present and the state of their preservation, the age and sex of the individual, their estimated stature, the presence of non-metric (possibly genetic) traits in the bones and also any pathological changes present in the bones and teeth.

An accurate assessment of **age** and **sex** of adult skeletal remains depends on good preservation and recovery of the **skull** and **pelvis**. These are the areas of the body that show the greatest degree of sexual dimorphism. The pelvis provides the surfaces that indicate the age of an adult individual (the auricular surface where the pelvic bones join the sacrum at the bottom of the spine and the pubic symphysis, where the pelvic bones meet at the front). The wear of tooth surfaces can also be recorded to provide an estimate of age. Care should be taken in the recovery of these elements, especially the pubic symphysis, which is prone to damage being located at the front of the body, thereby being one of the most protruding parts of the skeleton from the bottom

of the grave (if the body has been placed on its back, of course!). To age juvenile remains, the osteoarchaeologist analyses dental development and takes measurements of the long bones. This means that **long bones need to be recovered in one piece** if possible. This is also true of adult long bones, since these are measured to provide stature estimations. A detailed recording of non-metric traits and pathological changes requires as many bones to be recovered as possible. This is especially true of recording and diagnosing pathology – diagnosis of diseases is made upon observation of the distribution of pathological lesions around the body. So if a part of the body is missing or damaged it may be impossible make a specific diagnosis.

To make a good recovery of human skeletal remains, they need to be excavated thoroughly and lifted appropriately. In order to do this you need to consider the likely position of the bones in the ground and also to know what bones a skeleton consists of and how to excavate and lift them.

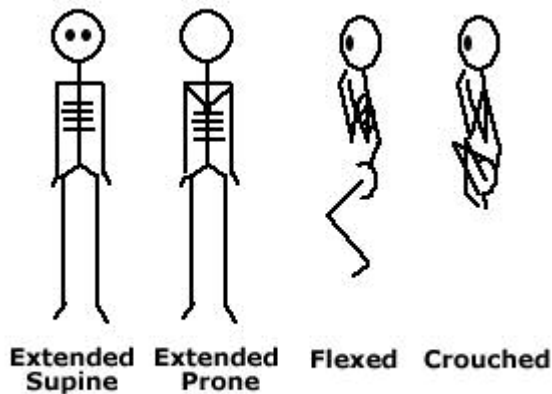
### **The Burial**

Disposal of the dead has varied tremendously throughout history in Britain. From rather grand prehistoric barrows to secreted deposition in wells, from intentional interment in crypts with coffin furniture, interment of babies under floors and in post-holes; from single burials, mass graves, isolated interments, planned burial grounds, to the collection of bones in ossuaries, human bone can be found almost anywhere at anytime! Whilst the location of medieval and post-medieval burial sites may be known from recorded sources, burials from earlier periods may only be found by chance from archaeological evaluations or during excavation. It is, therefore, of paramount importance that any human bones found and the context from which they came are recorded and excavated as fully as possible. Obviously, the interpretation as to the nature of the human remains and their funerary context can only be as accurate as the information provided by the excavator.



Prior to the Burial Act of 1847 (enforcing a minimum depth of 30" of soil to be placed between the coffin lid and the ground surface), burials often appear to be shallower. The original ground level associated with the burials may simply have been truncated by later activity or the graves may not have been dug so deep in the first place. This seems to be particularly the case with rural burials due to the erosion of ground levels through the action of ploughing and general exposure to the elements, although, of course, this is not true in all cases.

Rural contexts may contain isolated or small clusters of burials, especially from the late Iron Age and Roman periods, as well as larger burial grounds, such as Anglo-Saxon cemeteries. In the case of an isolated burial, it may be difficult to identify what the feature is until it is fully excavated, so care should be taken with all unidentified features. Some clues may exist: burials of this nature tend to be subrectangular in shape, located outside the main focus of domestic activity and may be aligned on a north-south or east-west axis. Small clusters of burials may be located in enclosures within field systems. However, it is not uncommon to find burials inserted into features initially dug or made for other purposes, especially during the Iron Age and Romano-British Periods. For example, bodies have been deposited in ditches, graves have been cut into banks and the remains of neonates have been found under floor layers and in postholes. In these cases, the location of skeletal remains may, on first impressions, appear to be random and can, therefore, be unpredictable.



Human remains from rural contexts tend to be deposited in a variety of positions – bodies may have been placed in an *extended* position in the ground. They may also have been placed on their side in a *flexed* or even in a very tightly *crouched* position. Most bodies are found to lying on their backs, or *supine*, whereas some are lying on their front, or in a *prone* position.

Some burials also have been found to contain individuals whose heads have been removed from their bodies – not infrequently skeletons dating to the Roman period, for example, have been found with the skull placed between the legs. Often, bones aren't quite where you were expecting them to be!

Many burials are found with grave goods, which require careful excavation as they may be very fragile. Also, the recording of the location of these goods in relation to the grave cut and the body is important. Some of the grave goods may contain articulated animal bones, possibly representing the remnants of food offerings given to the dead. The position of these should also be recorded carefully to distinguish them from other animal bones that are unintentionally included or intrusive in the grave back-fill. If you are unfamiliar with animal and human bone and are not confident about differentiating between the two, either ask your on-site osteoarchaeologist to help or record and recover any bone you suspect may be useful for interpretation of the feature, as you would do normally. As long as the location of bones are recorded properly, post-excavation analysis should clarify the information presented.



*These animal bones were found in a Roman grave. The recovery of the bones and the epiphyses, as well as the recording of their position in the ground, allowed an informed interpretation to be made about the finds. It is thought that these articulated remains of neonate sheep were deliberately placed above the body (possibly on top of a coffin) as a food offering.*

The location of human remains within the grave is also important to note, especially in the context of co-mingled remains in prehistoric tombs, where remains may have been removed and relocated for ritual purposes. It may also shed light on post-depositional natural site formation processes.

Burials in urban contexts may be found to be deeper and are likely to be part of complex stratigraphic relationships. There is a much higher chance of these types of burials having been truncated by other features as well as later graves. Burial activity in urban centres generally appears to have been intense at designated sites, such as around parish churches or public institutions like hospitals until the creation of out of town, large-scale cemeteries like Sheffield General Cemetery from the 1830's onwards. In this case, there is likely to be a high amount of disarticulated human remains resulting from the disturbance of earlier graves by later ones. Excavators will need to be able to distinguish between the disarticulated and articulated remains for the purposes of osteoarchaeological analysis – *it is important that bones referred to by one context number belong to the one and same person.* This is especially true of the excavation of mass graves.

Preservation conditions on sites and between graves on the same site vary a great deal. Some burials may have occurred in soils that leave no trace of the bones at all; for example, some sands and boulder clays are very acidic and this may dissolve the bones completely. However, careful excavation is still required; firstly, to recover grave goods that may have survived and secondly, a silhouette of the body may be observable in the form of a "shadow" in the soil. This silhouette, occurring as a dark stain in the soil, may even be excavated as a positive feature; that is as if the body itself were present and the soil form around it is being removed. This proves that the burial actually contained a body and signifies that the grave is not acting as a cenotaph (a memorial to the deceased whose body isn't present) and, therefore, provides a more informed insight into funerary practices. It may also demonstrate the position of the body in the grave. If the feature under excavation is isolated, the presence of an well-defined body stain would indicate that the feature was certainly a grave rather than, for example, a pit.

On the whole, the state of preservation of human bone is dependant upon a number of factors (such as soil acidity, hydrolysis, integrity of the grave, age and sex of the individual, animal activity etc) and since this can vary across a site it is not easy to predict how well bone will be preserved. Generally, it can be said that a more alkaline, free draining soil with little post-depositional activity will result in good bone preservation, though it should be noted that complete submersion of bone in water may also preserve bone well.

Crypt burials or later burials, especially in lead or solid wood coffins may also result in soft tissue preservation. This may include hair, fingernails and skin. These must be treated with caution for health and safety reasons. Precautions you need to take should be explained to you by your Site Safety Officer. *It is usually only the presence of soft tissue that causes any health and safety issues.* Again, careful excavation of associated grave goods, contextual recording of grave structures, coffin furniture and recovery of fragile materials such as textiles and organic items is required.

### **The Skeleton: so where do I start?**

If you suspect that the feature you are about to excavate contains human remains, you need to consider the contextual information you need to recover from the grave. For example, if you think that you may well be excavating a prehistoric barrow, will it be worth putting a section through the grave mound (if there's one remaining) or fill to reveal how the mound was built over the grave? For example, a linear patchwork of turves that have been cut and placed on top of the grave to form the mound may show up particularly well in section but not in plan.

It is generally common practice, however, to excavate the whole of the grave in plan, following the underlying assumption that the back-fill of the grave occurred as one event. It may be that different fills are found within the grave, where the original grave has been dug through different strata of soils. Caution must be taken not to undercut the grave; if the grave was cut through a layer of silt and the underlying natural, and subsequently the grave was backfilled with the natural and then the silt on top, the natural would end up being redeposited at the bottom of the grave and this would be the matrix surrounding the skeleton. If the redeposited natural is not recognised for what it is, the grave may be undercut and the skeleton not retrieved. The grave cut itself may not even be easily distinguishable due to the speedy redepositing of soil that is the same as the soil into which the grave was cut. In this type of scenario, if burials are suspected to exist, the area should be stripped back in shallow spits until bones are exposed. Boxing out test pits of the burial site to see if anything is there is more likely to result in loss of information, especially if the bone is not well preserved and the weather is inclement!

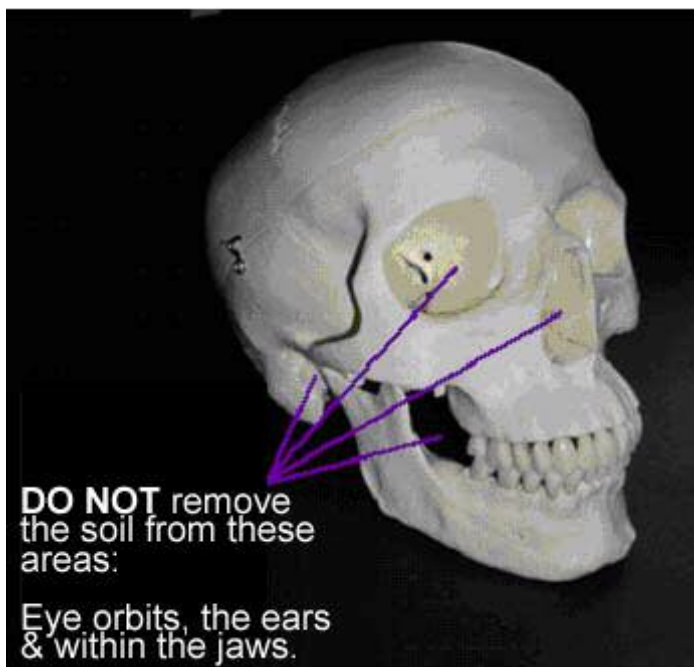
Happily, in many cases the grave cut can be detected in plan. So which end do you start? What tools do you use? Well, take a rational approach. Use tools that are appropriate for the likely depth of burial and state of bone preservation as you would on any other feature containing fragile objects. Generally, it's a good idea to start at the head end of the grave – so if the

grave is aligned east-west, the head should be at the west end of the grave and if the grave is north-south aligned then the head is likely to be at the north end. Remove the grave fill in spits from this end.

Caution must be taken in removal of the backfill to expose the skull. Where the body has been placed in an extended position, the cranium is the part of the body that projects out furthest from the bottom of the grave. The cranium also happens to be one of the most informative parts of the body for estimating the sex of the individual as well as their age from the teeth. Some pathological changes that are used to diagnose certain pathologies occur in the cranium, on the skull vault, around the eyes, nose and mouth. A whole cranium also allows the osteoarchaeologist to take measurements of it and to look for any pathological patterns of asymmetrical development. All too often, especially on commercially run sites, crania are broken and parts are even lost from using mattocks in the rush to excavate remains. So immediately analytical data is lost also. Also be aware that whilst working you're actually walking up and down on the rest of the body, which contains the particularly fragile rib bones so it may be appropriate in more silty or sandy soils to work from a plank or board placed across the grave cut.

**DO NOT** excavate soil from within

- the eye orbits
- the nasal aperture (nose)
- the auditory meatus (ear)
- the mandible (lower jaw) – leave a flat section across one side of the jaw bone to the other.
- any holes that occur in any of the bones that may be the result of disease



The eye sockets contain delicate bones that are easily damaged and, therefore, you should not attempt to remove soil from within them. The soil from within mandible, likewise, should not be removed as there are small bones and potentially pieces of ossified cartilage contained within this area that are easy to miss and/or damage. Also the ear contains three very small and fragile bones and should be left with the soil in.

Below are some examples of the bones you might find in the jaw area:



Hyoid Bone: Present in all people, contained within the jaw area in the throat.

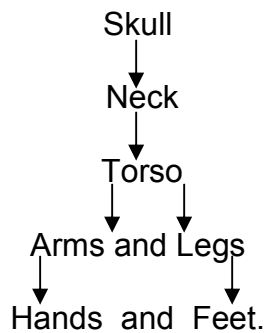


Thyroid Cartilage: Present in some people, contained in the jaw area – very fragile ossified cartilage

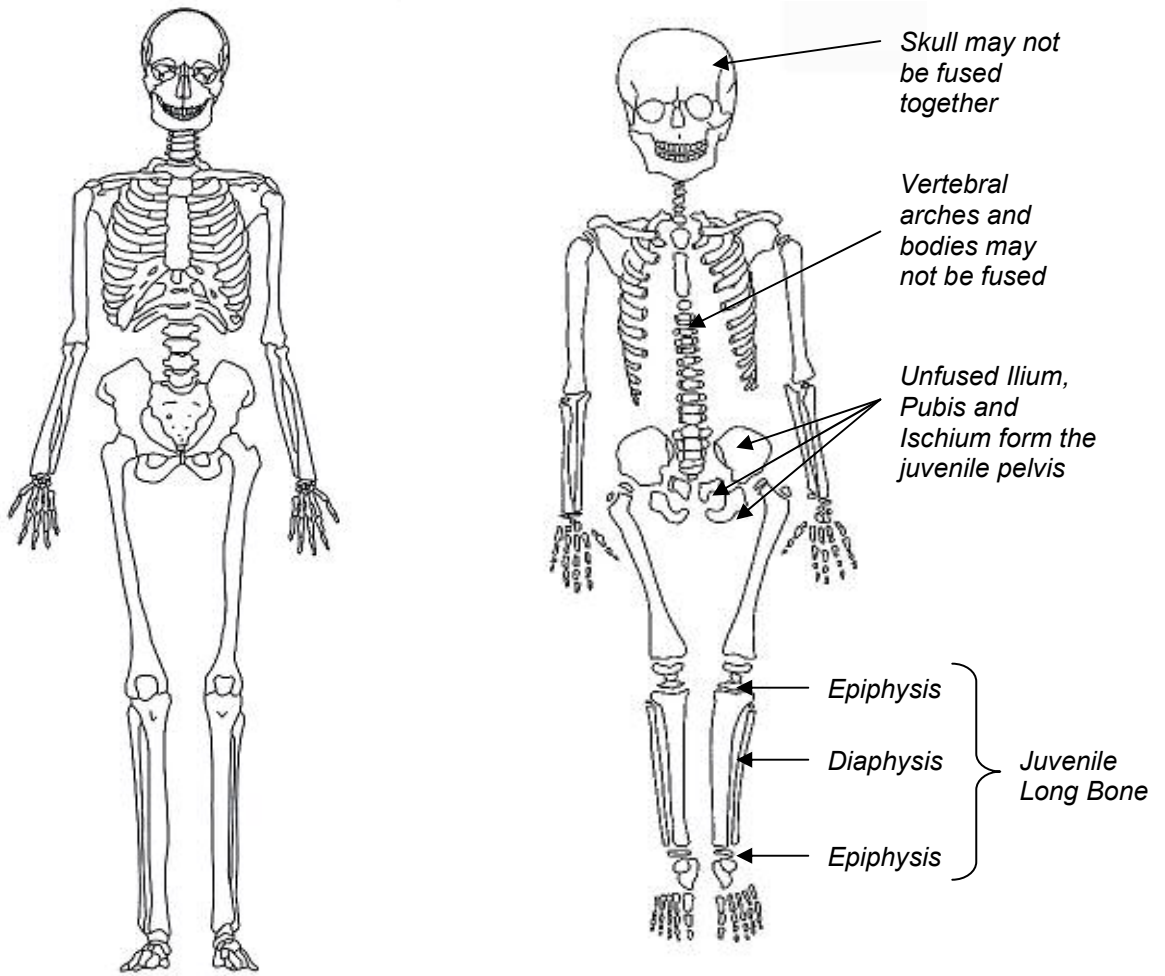


Cricoid cartilage: Present in a few people, contained in the jaw area – very fragile ossified cartilage

Once you have exposed the skull, you can work your way down the remains using a plasterer's leaf trowel in sequential order of body areas i.e.



This, of course, may be easier said than done depending on the position of the body in the grave but it helps to follow a logical sequence of which bones articulate (or are joined) with which, demonstrated in the diagram below:



*Adult Skeleton in anatomical position*

*Juvenile Skeleton – note unfused long bones and pelvis*

Note that the bones of juvenile skeletons are not fused as they are not fully developed. The long bones come in three parts – two ends (epiphyses) and the main shaft or diaphysis. There may also be additional smaller epiphyses that attach around the end of the bones. Extra care should be taken when excavating juveniles as these extra bones are susceptible to post-depositional movement. Some bones may resemble small stones and may be difficult to identify, especially in infants and neonates. When excavating the remains of young individuals, it is a good idea to retain all the soil from around and underneath the skeleton as a sample to be processed later for retrieval of smaller bones. Neonates should be block lifted.

At this stage, if excavating an adult or older juvenile, you should remove as much soil as is required to reveal to extent of the bones (and associated finds) and their position in the ground so that can be clearly seen for recording and photographing. Be careful not to remove so much fill that the bones move from their original position or to scrape the bone surface with your trowel – if soil conditions allow it use a brush to remove the soil from the bone surface.

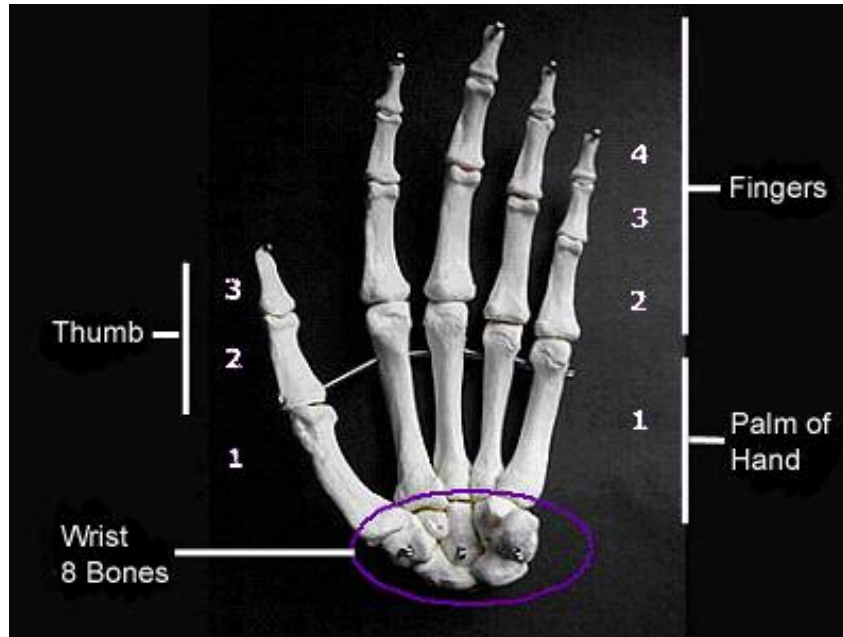


*Post-mortem damage caused to the surface of an otherwise well preserved femur by using a mattock to excavate grave fill. It is better to excavate the back-fill with a trowel until the depth of the burial is known.*

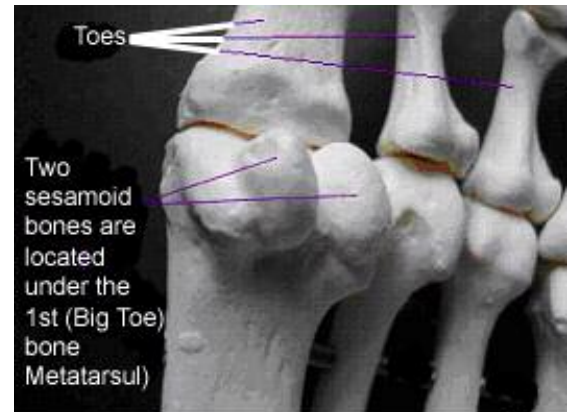
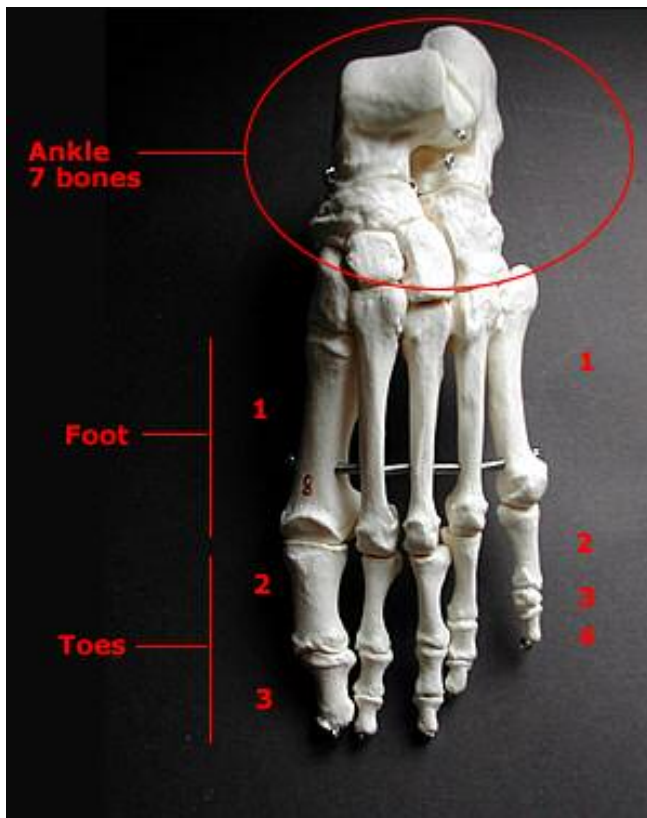


*Careful excavation with appropriate tools ensured the survival of this fragile fragment of shroud preserved on the tibia of this individual.*

Care also needs to be taken when excavating hands and feet as these contain small bones that are easily disturbed through post-depositional activity such as animal and worm burrowing. If the bones are in a state of good preservation, it is possible to excavate and recover all of the bones, which is of great help to the osteoarchaeologist as there are some diseases that can only be diagnosed through observation of pathological changes to the bones of the hands and feet, such as rheumatoid arthritis. The plates below demonstrate the bones of the hands and feet, how they articulate and what they look like.



*The Bones of the Hand: this hand is palm side up or in the supinated position. Note that there are 8 separate bones in the wrist and that the fingers have three rows of phalanges (2,3 and 4), whereas the thumb has only two (2 and 3).*



*Note that there are two small bones located underneath the first big toe bone or 1<sup>st</sup> metatarsal. These are called sesamoid bones and would have been situated within the tendon to strengthen the big toe joint to cope with the stress created by "toeing off" when we walk.*

*The Bones of the Foot: the ankle area of the foot is made up of 7 individual bones. Similar to the fingers, toes are made up of three rows of phalanges (2,3 and 4), whereas the big toe consists of two rows (2 and 3).*

If you feel that post-depositional movement of the bones of the hands and feet has occurred, then it may be a good idea to collect some of the soil from the surrounding area to be processed in order to retrieve as many bones as possible. It is not possible for the osteoarchaeologist to tell left from right phalanges (rows 2, 3 and 4 in the figures above) in either the feet or the hands, so the excavator should be careful to follow the articulated fingers and toes of each hand and foot. This is especially true if the hands or feet overlie each other – if the hands or feet are lifted together it will not be possible for the osteoarchaeologist to determine which phalanges belong with which hand or foot. The right and left sides need to be bagged up separately, clearly labelled with the side they are from. In some instances, where bones are not disturbed and are well preserved, the position of the hands and feet may indicate the time of burial of the individual after they had died. If the body was still in a state of *rigor mortis*, the hands and feet may look “clenched” due to the contraction of the muscles in the arms and feet. This is also true of victims of fire incidents. Although this is rare, it is useful to bear this in mind when excavating the extremities, as this kind of evidence can only be revealed by careful excavation and recording.

Excavation of the torso area should also be mentioned here as the soil surrounding the vertebrae and ribs may contain cysts, which look very like small stones. If you are in any doubt, collect anything resembling cysts or ask your on-site osteoarchaeologist. It may be that you have been asked to take samples from the gut area of the skeleton, in which case the soil from this area will be recovered for this purpose. You may also find that at the rib ends, costal cartilage has ossified as dense, irregular lumps of bone (in life, the ribs are held together by costal cartilage to form a basket like structure). This is usually associated with older age.

Also, be aware that the kneecaps or *patellae* are prone to slipping to one side or the other of the leg bones. Patellae are not directly fixed in position with the leg bones and lie above the end of the thigh bones (femora). Once excavated, they are extremely easy to lose, especially in an extended, supine skeleton, as only the soil around them keeps them in position. It may be safer to note which is the left and right patella, place them somewhere safe whilst you are excavating the rest of the skeleton and later replace them when recording and photographing. Alternatively, if the skeleton is on its side and flexed, you may wish to leave a block of soil underneath the patellae to maintain their position in the ground.

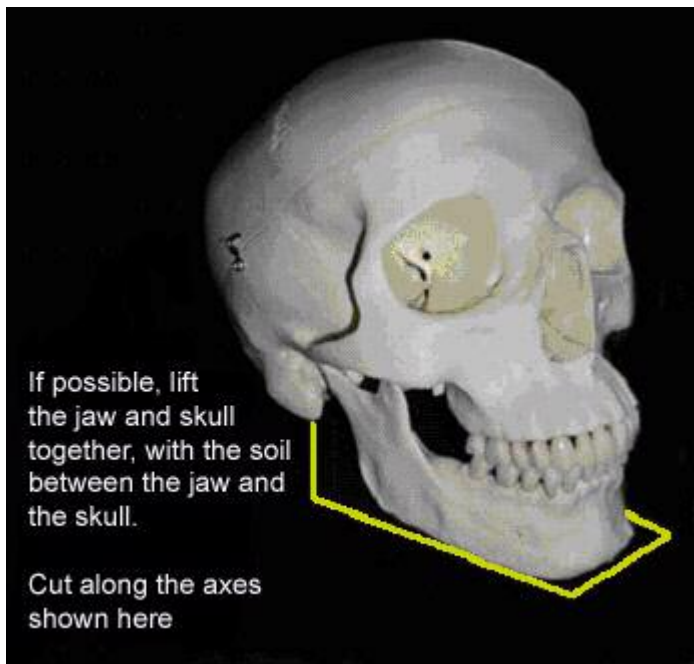
Finally, you need to be aware that the small bones of a foetus that has died in the womb may be present in the pelvic area of any female body. These bones are very fragile and also susceptible to post-depositional movement. It is recommended that, unless conditions are excellent and the bones are very well preserved, that the pelvis is block lifted and the soil from around the pelvis contained. If excavation of neonate remains is attempted, it may be best to use wooden spatulas or ‘skewer’ sticks with rounded ends. You should

also be aware that small infants or neonates have been discovered alongside or at the feet of an adult in one burial cut.

At the stage when full extent of the skeleton has been fully exposed, record the skeleton as you have been instructed. This should include the bones present, body position, head position, grave alignment, associated finds, samples, structures and features. Any abnormalities about the body (spinal or limb deformities) that can be spotted at this stage should be noted and close-up shots taken with a scale. A plan of the skeleton, associated finds and grave cut should be made and photographs taken, either digitally or manually. If manually recording the skeleton, it is traditional to take levels of the skeleton at the head, pelvis and feet.

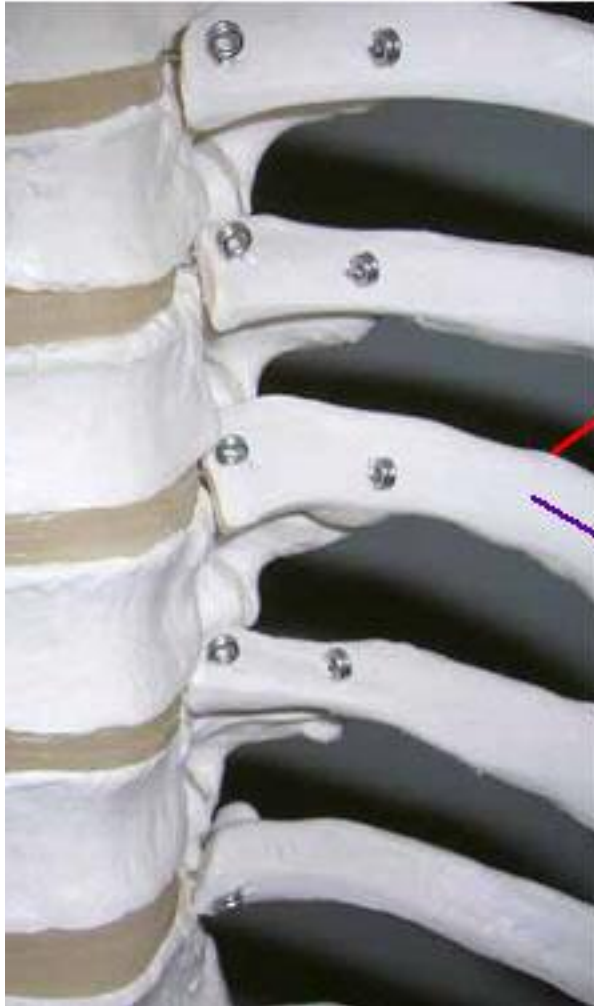
### **Lifting the Skeleton**

Once the skeleton is fully recorded, it is ready to be lifted. At this point you need to remove as much soil as possible (except where mentioned above) from the bones before lifting them out of the ground. This relieves the bone you're lifting of any pressure of resistance from the surrounding soil and the bone is much less likely to break. Start removing the bones in the same order you excavated them in, starting with the skull and working down. **Never wrench bones out of the ground:** always ensure you have removed enough soil to remove the bones freely. Bag the bones up as instructed by your site supervisor; in general, bag bones up as you lift them with the appropriate labels, keeping left and right side limbs separate.



When removing the skull, try and remove it with the jaw in one block if possible, due to the fragile bones contained in the upper neck region: cut the soil along the axes shown in the diagram to recover the soil contained between the mandible and the cranium. Be careful to recover any loose teeth that may be lying in the surrounding soil, as these are a great source of information for estimating age and sex of the individual as well as being used for DNA and chemical analysis.

The bones that are undoubtedly the trickiest to remove are the vertebrae and ribs, as they are interlocked as illustrated below:



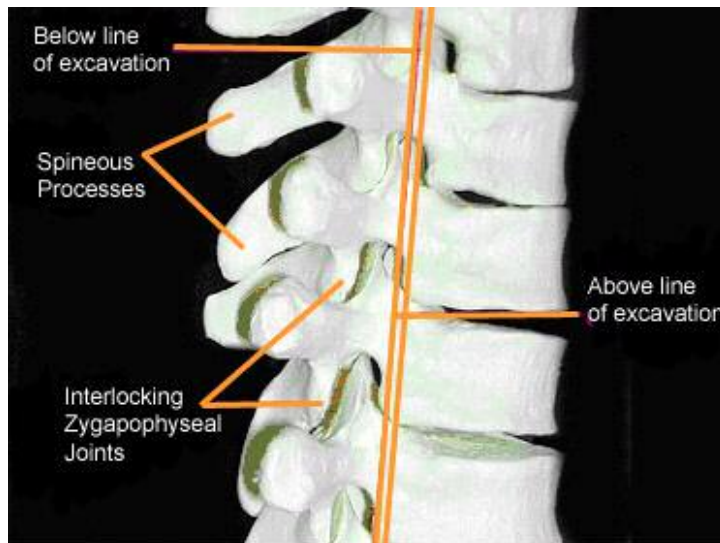
*Once the surrounding soil has been removed from the whole rib and vertebrae, place the leaf trowel behind the rib here. Support the rib shaft and rib head with the trowel and your fingers.*

*Lift the rib away from the vertebra in this direction, following the length of the rib shaft, gently twisting the rib towards you with the leaf trowel whilst still supporting the rib with your fingers.*

In this instance, you need to remove as much soil as possible from around the ribs and the joint between the rib and vertebra, especially underneath it. Starting with the top rib, when you can feel that the rib is loose, place your leaf trowel underneath the rib as close to the joint as possible and peel the rib away from the vertebra, **gently** twisting and pulling it towards you with the trowel. The force generated by lifting the rib in this fashion is more likely to travel along the length of rib and, therefore, it is less likely to snap. It is also a much faster technique to employ in the long run when you've got the hang of it!

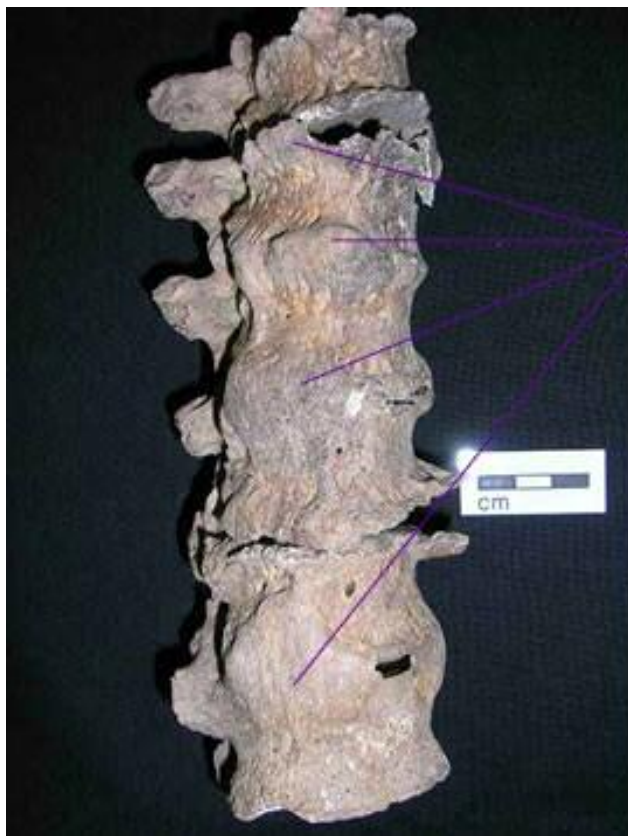
Once all the ribs have been removed, the next step is to remove the interlocked vertebrae. Start at the top (this vertebra should be easier to remove as it has been left exposed by removal of the skull) and remember to remove soil from underneath the vertebra. The spine of the vertebrae are embedded in the ground when the body is supine and it is this that generally makes them difficult to remove. If too much soil is left around the spine of the vertebrae when you try and lift them, the spines are likely to snap off the main

body. Again, enough soil should be removed from around and underneath the vertebrae to ensure they are loose before lifting is attempted. When the top vertebra is loose, place your leaf trowel between it and the vertebra beneath and **gently** lift the top vertebra up and away.



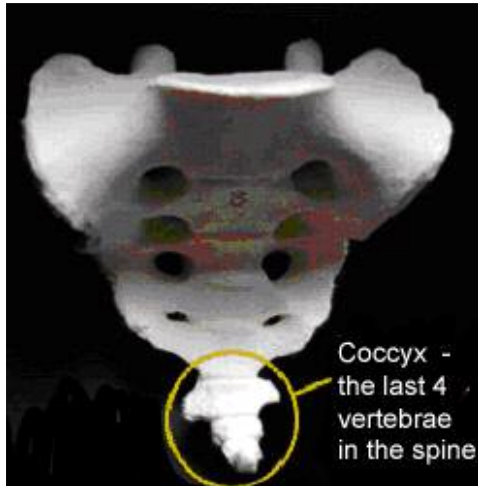
*If the skeleton is in an extended, supine position in the ground, it is likely that only the bodies of the vertebrae will be exposed for recording. For lifting, removal of the soil underneath the bodies from round the spinous processes is required, otherwise, due to the interlocking of the vertebrae, the processes will snap off.*

It should be noted that often diseases of the spine result in some vertebrae being joined through bony bridges – some of which are more obvious and sturdier than others. Therefore, *not all vertebrae can be lifted separately*. If a block of two or more vertebrae appear to be joined in this way, then lift them in the block. Do not try and force any vertebrae apart.



*These vertebrae are fused together by osseous or bony growths (in this case caused by ossification of the anterior vertebral ligament due to DISH). Vertebrae like these need to be block lifted. Care needs to be taken during lifting not to snap the bony growths holding the vertebrae together.*

If soil conditions are heavy and resistant to lifting, such as in clay, lift the vertebrae in blocks anyway. It is better for the vertebrae to be separated during the washing process than to be broken at the excavation phase. It should be noted that this is the rule for any bones – *any bones may be fused together due to pathological processes.*



Remember that a small block of vertebrae exist adjoining and sometimes fused to the bottom of the sacrum (see photo) called the coccyx. If they are not fused to the sacrum, these bones are also likely to be lost due to post-depositional activity. They are contained within the pelvis area.

Of course, not all bones are well preserved and **some may be more fragile than others due to pathological processes.** For example, if a leg bone is infected, the bony remodelling that occurred during the process of inflammation will result in more fragile bone being developed. If you come across any fragile bone(s) that may not withstand being lifted individually, block-lift the bone(s). The surrounding soil can then be more gently removed through washing.



*The bony remodelling visible here in the left knee (the result of an infection in the knee joint) has weakened the original bone. The fragile nature of this bone has caused the upper bone (femur) to break near the joint when lifting was attempted.*

To conclude, the excavation of human remains requires adequate care – hopefully this guide will have provided a few pointers to bear in mind when tackling the recovery of human bones:

- Know your bones! Is the skeleton an adult or a juvenile?
- Be aware that the skeleton could be lying in one of a number of positions. Bones may not be where you are expecting them to be!
- Remember that there may be more than one individual in one burial cut – infants may have been placed alongside or at the feet of adults
- Make sure the bones belong to the same skeleton
- Use the appropriate tools to carefully remove the surrounding soil. Do not remove the soil from any holes or from within the jaw of the skull.
- Expose the bones well enough to clearly indicate their position and to reveal any fused or pathological bones but cautiously to prevent damage to the bones and their surfaces
- Record the skeleton and its associated finds/samples thoroughly
- Bones are fragile – remove enough soil so that bones can be lifted easily. Block lift neonates and more fragile bones as appropriate.

*And, of course, please treat all human remains with the respect and dignity they deserve at all times. It is a privilege, not a right, to excavate human remains.*

For more detailed information regarding the excavation and processing of inhumated human remains and also cremated bone, please see the excellent **IFA Technical Paper Number 13** by Jacqueline I McKinley and Charlotte Roberts.

## **Appendix 1**

More detailed guidance regarding the recovery of human remains can be found at:

**England:** Church Archaeology Human Remains Working Group Report:  
<http://www.english-heritage.org.uk/default.asp>

**Ireland:** Heritage Council Publication, Human Remains in Irish Archaeology:  
[http://heritagecouncil.ie/publications/human\\_remains/hr\\_printer.html](http://heritagecouncil.ie/publications/human_remains/hr_printer.html)

**Scotland:** Historic Scotland Operational Policy Paper 5.  
<http://historic-scotland.gov.uk>

Other useful Links:

OssaFreelance  
<http://www.ossafreelance.co.uk>

**Spoilheaps** excellent guide to Burial Archaeology.  
<http://www.spoilheap.co.uk/burial.htm>